

Heart Disease in the Older Cat

Kerry Simpson

FAB Lecturer in Feline Medicine, University of Edinburgh

The term cardiomyopathy simply refers to a disease of the muscular wall of the heart. There are several different type of cardiomyopathy reported in the cat. Many of these mimic diseases seen in human beings and for this reason the same classification system has been applied to cats. This classification system makes the distinction between the primary cardiomyopathies and 'specific cardiomyopathies', in which myocardial dysfunction occur secondary to a known aetiology. The primary cardiomyopathies described in humans include dilated cardiomyopathy (DCM), hypertrophic cardiomyopathy (HCM), restrictive cardiomyopathy (RCM), arrhythmogenic right ventricular cardiomyopathy (ARVC) and persistent moderator band cardiomyopathy. Unfortunately, as a disease progresses and areas of ischaemia and infarction occur, the features of the underlying disease may become masked. At times, the term unclassified cardiomyopathy (UCM) is used to accommodate cases in which salient features of more than one disease group may be present. In addition to the primary cardiomyopathies, there are many specific cardiomyopathies which occur in the cat. Secondary or specific cardiomyopathies arise from systemic diseases such as hypertension and hyperthyroidism, which have an effect on the heart. Both hyperthyroidism and hypertension are common in the older cat and so is heart disease associated with these conditions.

Primary Cardiomyopathies

Prior to 1970, the feline cardiomyopathies were recognised only in association with aortic thromboembolism. In 1970, Liu published the first report describing acquired cardiac lesions which culminated in congestive heart failure. Over the subsequent decade, various reports were published detailing the gross anatomical and histological features of the feline cardiomyopathies. At that time, cardiomyopathy was detected in 8.5% of cats that underwent post-mortem examination. Initially, DCM and HCM were reported to be the most prevalent of the feline cardiomyopathies. However, in 1987, Pion and colleagues discovered a causal relationship between decreased plasma taurine levels and feline myocardial failure. With the supplementation of commercial cat food with taurine, the incidence of feline 'DCM' has decreased making HCM the most prevalent feline cardiomyopathy today.

Hypertrophic Cardiomyopathy

Cats have been diagnosed as having HCM from the age of two months to 24 years with a reported mean age of naturally occurring HCM being between 4.8-7 years.

The most commonly reported affected 'breeds' are the domestic shorthaired (DSH) and longhaired (DLH) cats. In addition, Persian cats have been reported as being predisposed to HCM and high incidence of disease has also been reported in the Maine Coon, the Birman, Sphinx, Siberian and the Ragdoll breeds.

Restrictive Cardiomyopathy

The term restrictive cardiomyopathy (RCM) is applied to primary heart muscle disease that restricts the diastolic ventricular function and excludes HCM. There are no sex predilections, and the age of affected cats is highly variable, but typically middle to old aged animals are affected.

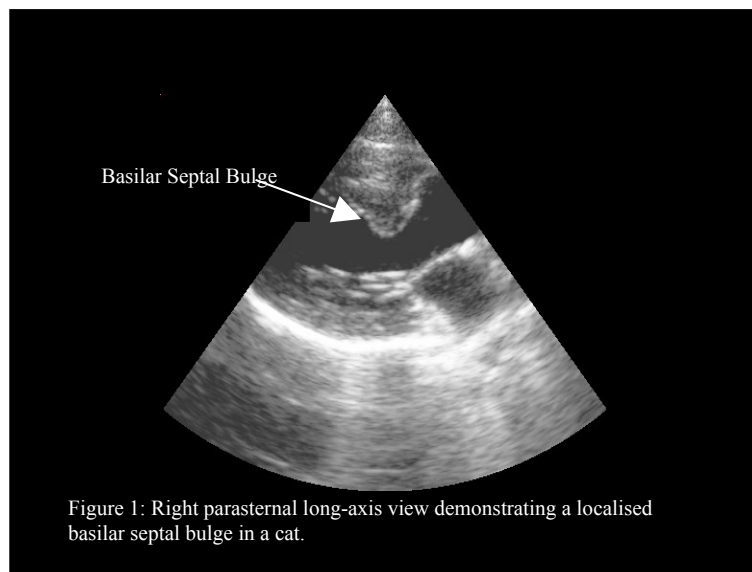
Dilated Cardiomyopathy

Since the discovery of Taurine deficiency in cats, the incidence of DCM has decreased, with approximately 3% of cats with cardiomyopathy suffering from systolic myocardial failure (DCM). Whilst some of these cats remain Taurine deficient, either through poor diet, or metabolic anomalies, others appear to suffer from a familial DCM. In addition, isolation of viral DNA has been isolated from cats' hearts with DCM, and it has been hypothesised that some cases may be caused by an infectious myocarditis.

Clinical Findings

Feline cardiomyopathies are a highly heterogeneous group of diseases and therefore, the associated clinical signs are highly variable. Since many cats are asymptomatic, apparent unexpected sudden death may occur. In others, stress may induce an increased respiratory effort, sometimes with acute pulmonary oedema or pleural effusion being seen. Other reported clinical signs include a rapid respiratory rate, anorexia, vomiting, fainting or the inability to move one or more limbs.

Aged cats are commonly identified with a dynamic murmur. Echocardiography typically identifies turbulence within outflow from the heart. In addition, many of these cats have a localised area of hypertrophy at the basilar portion of the interventricular septum. This causes a dynamic outflow obstruction and the presence of a heart rate dependant murmur. However, it has not yet been determined whether this basilar septal bulge (BSB) is a localised form of hypertrophy common in older cats, or whether it is a normal aging change.



Specific Cardiomyopathies

There are many different forms of specific cardiomyopathy reported in man, and many of these also apply to the cat. Amongst the most common are thyrotoxic cardiomyopathy, and hypertensive cardiomyopathy. Other potential causes of cardiomyopathy include Uraemic cardiomyopathy and diabetic cardiomyopathy. However, at present there is no convincing evidence that either of these diseases initiate significant heart disease in the cat. Less common causes of myocardial disease include acromegaly and infiltrative or inflammatory disease.

Diagnosis of specific diseases culminating in myocardial disease can be highly satisfying, as diagnosis of an underlying disease, increases the potential for 'cure', a scenario that is rare in cardiology.

Hypertension in the Cat

The term 'systemic hypertension' (HT) refers to a state in which the blood pressure is raised above the reference range. This may be due to an increase in the tone within the blood vessels (peripheral vascular resistance (PVR)), an increase in the circulating volume (hypervolaemia), or a combination of both. Chronic elevation of systemic blood pressure results in damage to multiple end-organ systems such as the brain, heart, kidneys and eyes. Systemic blood pressure is comprised of the pressure within the circulatory system during cardiac contraction (systolic blood pressure) and during cardiac relaxation (diastolic blood pressure). It has been demonstrated that either systolic or diastolic HT (or both) can lead to organ damage.

The normal control of blood pressure is very complex, consisting of many interacting systems, which together produce appropriate responses to a wide variety of stimuli. These mechanisms can mediate acute or chronic alterations in blood pressure. The acute responses are controlled by regulation by the nervous system; occurring in response to pressure changes within the circulation, and by the controlling the tone within the blood vessels. In the longer term, blood pressure control is also dependent on regulation of blood volume and therefore the hormones regulating this.

Feline Hypertension

In the cat, essential (primary) hypertension (as occurs in humans) is rarely encountered. Most cases of hypertension have been documented secondary to other diseases, the most common of which is chronic renal failure (CRF). Between 61% and 73% of cats diagnosed with systemic hypertension have elevated renal parameters. However, when the incidence of hypertension in a population of cats with CRF was investigated, it was found that, only 19.4% of cats were hypertensive. Other documented causes of feline hypertension include an overactive thyroid gland (hyperthyroidism), diabetes mellitus, some types of tumour (acromegaly, pheochromocytoma), increased secretions from the adrenal glands (hyperadrenocorticism, primary hyperaldosteronism), over active parathyroid glands (hyperparathyroidism) and an elevated blood calcium level (hypercalcaemia), and anaemia. There are also some reports of primary (essential) hypertension. However, at this stage it is still unclear whether or not this is a primary disorder comparable to essential hypertension in man, since it is difficult to rule out all other possible diseases.

Whatever the inciting cause of the elevation in blood pressure, there is always one common feature; pressure overload of the circulatory system. In addition, there are many effects on the aspects of nervous and hormone systems. Some of these may be specific to the precipitating disease; others may be stimulated by organ damage secondary to the pressure overload.

Systemic Effects of Hypertension

Unfortunately, the signs of hypertension are often not apparent until severe damage has occurred. With a rise in systemic blood pressure, some organ systems are more at risk than others; these are referred to as 'target organ systems' (Table 1).

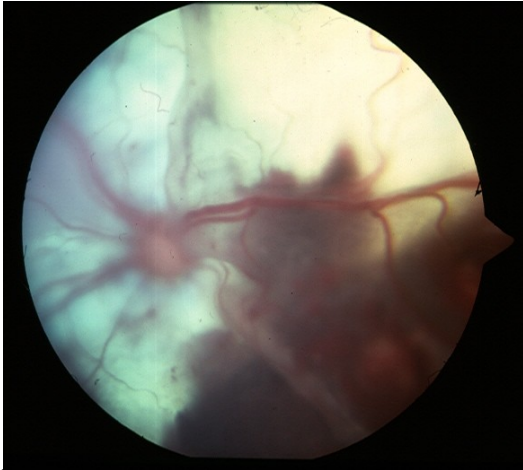


Figure 2a: Retinal haemorrhage in a hypertensive cat



Figure 2b: Epistaxis can be seen secondary to hypertension

Table 1: End-organ effects of Hypertension

Effect of HT	Effects More Likely	Conclusion
Kidneys Enhanced rate of decline of renal function Nephron loss	If SBP > 160 mmHg	Often difficult to determine whether renal disease is a cause or effect of HT
Eyes Exudative retinal detachment Retinal or vitreal haemorrhage, hyphaema Retinal vessel tortuosity	If SBP > 180 mmHg	Referred to as "hypertensive retinopathy/choroidopathy"
Brain Disruption of blood flow Fibrinoid arteriolar necrosis Thrombosis with hypoxic damage Cerebral swelling/oedema	If SBP > 180 mmHg acutely	Clinical signs result from ischemic stroke and/or hemorrhagic damage
Heart Concentric left ventricular hypertrophy promotes ischemia Secondary murmurs/gallop rhythms	Unknown	Cardiac changes may resolve with successful antihypertensive therapy

Modified from:

Stepien, R.L. *Blood Pressure Measurement: Equipment, Methodology and Clinical Recommendations of the American Consensus Panel*. in *22nd Annual Forum of the American College of Veterinary Internal Medicine*. 2004.

Cardiac Affects of Feline Hypertension

Early reports of hypertension in cats alluded to a relationship between high blood pressure and cardiac murmurs, gallops or cardiomegaly. In one such study, 81% of the cats

examined were found to have cardiomegaly. Furthermore, within a population of cats with left ventricular hypertrophy 47.5% were found to be hypertensive.

Recently, more detailed reports of the echocardiographic changes in hypertensive cats have been published. It has been found that compared to age matched control cats, cats with an elevated systolic blood pressure, typically demonstrate hypertrophy of the interventricular septum, posterior wall or both. However, the degree of hypertrophy appears variable. In some cases the ascending aorta has been reported to be dilated, as have atria. Interestingly, two different groups have commented that a common feature in hypertensive cats is a localised area of hypertrophy affecting the basilar septum.

In addition to its effects on the heart, hypertension has many other effects on other organs including the kidneys. Increasing the renal perfusion pressure elicits damage to the glomerulus, hyaline nephrosclerosis, and may eventually cause renal failure. It is still unclear as to whether or not the high incidence of azotaemia within the hypertensive feline population is a primary or secondary problem. This is frequently complicated because hypertension is not diagnosed until ocular signs, such as retinal haemorrhage are seen, at which time the blood pressure is often highly elevated, and may have been so for some time.

Treatment of Feline Hypertension

Since there are so many different mediators involved in the development of end organ damage, there remains much controversy as to the ideal treatment. There are three classes of drugs commonly used to treat feline hypertension, and there are advantages and disadvantages to each.

The most popular group at present are the calcium channel blockers, or more specifically, amlodipine: A channel blocker with predominately vascular effects. Within the wall of the arteries there is a muscular layer. For this muscular layer to contract calcium influx is needed. By blocking the influx, calcium channel blockers promote dilation of peripheral arteries. Amlodipine has been demonstrated to be very effective at lowering feline blood pressure.

Another group of drugs commonly used in feline hypertension are the ACE inhibitors. However, as a group they appear fairly unreliable at decreasing blood pressure. A possible explanation for this may be that the hormonal axis which these drugs target (the renin-angiotensin-aldosterone system (RAAS)) is not activated to the same degree in cats as in humans. It has been demonstrated that there is a small but significant reduction in systemic hypertension when benazepril is administered to cats with induced renal insufficiency.

The third most commonly used group are the β -blockers. These decrease blood pressure by decreasing cardiac output and renin release. The most common use of β -blockers is in the reversal of hypertension secondary to hyperthyroidism when there is an increase in the number of β -receptors. In cats suffering from chronic renal failure and hypertension, the β -blocker propranolol was found to be ineffective as a long-term sole therapy.

The study of feline hypertension is a relatively new field and as such there remain many unknown factors. At present, the most common hypertensive treatment (amlodipine) appears not to effect all the secondary changes, but be relatively adept at reducing the blood pressure.

Thyrotoxic Cardiomyopathy

Hyperthyroidism is now recognised as the most commonly occurring endocrine disorder in the domestic cat, the incidence of which is approximately one to two per cent. It is a disorder of the thyroid gland leading to overproduction of T4 and T3. This is usually caused by a functional thyroid adenoma involving one (30%) or both thyroid lobes (70%), with less than two per cent of cases being caused by a follicular or papillary carcinoma.

Clinical Features of Feline Hyperthyroidism

Hyperthyroidism is a disease that can affect cats between the ages of 6 and 20 years (mean age 11-12 yrs). There do not appear to be any breed or sex predilections, although in the Siamese breed appears to be protected. The elevation in thyroid hormone levels affects many systems and for this reason clinical signs can be quite diverse. The most common reasons for initial presentation are polyphagia, weight loss, diarrhoea, intermittent vomiting, hyperactivity, polyuria and/or polydipsia. On physical examination a palpable thyroid goitre is often noted (70-90% of cases), affected cats are usually thin, with reduced muscle mass, may be short tempered, often have a raised resting heart rate, can be hypertensive and may have a systolic heart murmur. Diagnosis is usually made by demonstrating increased circulating levels of total T4. However, two to ten per cent of hyperthyroid cats have a resting T4 in the normal range and in these cats it is necessary to demonstrate the over activity of the thyroid gland by means of a thyrotrophin releasing hormone (TRH) stimulation test or a T3 suppression test.

It has been reported that abnormalities of the cardiovascular system can be found on physical examination, in 95% of hyperthyroid cats, and that most cats examined show changes similar to those seen in HCM (with only occasional cases resembling DCM). The most common alterations within the cardiovascular system are, hyperkinetic femoral pulses (91.2%), systolic murmurs (44.7%), gallop sounds (31.5%) and sinus tachycardia (26%). Echocardiographic examinations have revealed that a proportion of cats with hyperthyroidism demonstrate left ventricular wall hypertrophy, interventricular septal hypertrophy, left atrial dilatation, and an increase in left atrium to aortic diameter, similar to the changes seen in HCM.

Treatment

Hyperthyroidism is largely a treatable disorder. Options for treatment include; oral anti-thyroidal medication (such as methimazole, or carbimazole), surgery, or radioactive iodine therapy, or a combination of medical treatment followed by surgery. Some cats will require concurrent medications, most frequently to correct the associated heart disease.

Post-treatment the majority of cardiac signs usually resolve and most cats do not require maintenance on cardiac medications. Studies have demonstrated that the majority, but not all of cardiac alterations reverse if a stable euthyroid state is maintained. The remaining changes may be due to damage invoked by the increased activity that has been imposed on the heart, or it may be because hyperthyroidism is a disease of older cats and they may have had a mild underlying cardiac condition that the hyperkinetic state has exacerbated.

The changes seen in the hyperthyroid heart have been demonstrated to occur as a result of the direct action of T3 on the heart, changes in the periphery, and interactions between thyroid hormone and the sympathetic nervous system. These effectively cause an increase in force and rate of contraction and an increased speed of relaxation, giving rise to the syndrome of 'thyrotoxic cardiomyopathy'.

Feline Seizures

Nicki Reed

FAB Senior Clinical Scholar, University of Edinburgh

Introduction

Normal electrical activity within the brain is a balance between excitation and inhibition, which allows transmission of electrical impulses from one area of the central nervous system to another. A seizure is a transient period of clinical abnormality that arises as the result of a disturbance in electrical activity within the part of the brain known as the cerebral cortex.

Classification of seizures

Classification of seizures may help in identifying an underlying cause, but the classification of seizures is not always straightforward, with classification systems borrowed from human medicine not always being appropriate for animals. Broadly speaking, seizures may be classified according to aetiology (cause), frequency, or appearance.

- Classification according to aetiology
 - *Primary/idiopathic* – seizures due to an unknown cause.
 - *Secondary/reactive* – seizures arising in response to an underlying metabolic or toxic disease. These are usually reversible if the underlying disease is identified.
 - *Symptomatic* – seizures due to an identifiable abnormality within the brain, either structural or physiological.
 - *Cryptogenic* – a symptomatic cause is suspected, but not identified.
- Classification according to frequency
 - *Epilepsy* – a chronic condition of recurrent seizures
 - *Cluster seizures* – frequent recurrence of seizures within a 24 hour period, but the animal regains consciousness between seizures.
 - *Status epilepticus* – a state of continuous seizure activity. Seizures in excess of 20-30 minutes may cause irreversible brain damage.
- Classification according to area of brain affected
 - *Generalised seizures* – both cerebral hemispheres are involved
 - Convulsive
 - Non-convulsive
 - *Partial seizures* – the seizure occurs in a focal part of the brain
 - Simple
 - Complex
 - *Partial seizures with secondary generalisation*

Investigation of Seizure Disorders

Seizures require to be differentiated from other conditions that may give rise to periodic collapse:

- *Syncope* – a loss of consciousness due to diminished blood flow to the brain
- *Narcolepsy* – a loss of consciousness, accompanied by falling over (flaccid)
- *Cataplexy* – a short, sudden loss of muscle tone, but consciousness is retained

History

The history provided by the owner may be invaluable in reducing the list of differential diagnoses. Of importance are such factors as

- Age at onset
- Frequency, duration and progression of seizures
- Timing of seizures in relation to feeding, sleep, exercise
- Signs actually exhibited at times of episode
- Any other signs suggestive of a systemic disease

Physical Examination

A full general physical examination may detect signs of systemic disease. In addition, a neurological examination may detect subtle abnormalities that may suggest intra-cranial disease. However, cats are notoriously difficult to perform neurological examinations on!

Differential Diagnoses

There are many potential causes of seizures in cats (see Table 1). The initial history and physical examination may enable a short list of potential diagnoses to be made, after which more specific tests may require to be performed.

Further Investigations

- Haematology: blood counts of red blood cells, white blood cells and platelets to investigate anaemia (low red cell count), polycythaemia (excessive red cell counts), thrombocytopenia (low platelet counts), leucaemia (excessive white cell counts) or inflammatory disease.
- Routine biochemistry: to assess liver and kidney disease, and metabolic disorders such as hypocalcaemia (low calcium), hypokalaemia (low potassium), hypo or hyperglycaemia (low or high blood glucose), and hypernatraemia (high sodium).
- Urinalysis: to investigate kidney disease, liver disease and diabetes mellitus
- Blood pressure measurement: to rule out hypertension (high blood pressure)
- Other blood tests: infectious agents, lead levels, clotting profiles, hormone levels
- Imaging of the brain (MRI better than CT)
- Electroencephalogram (EEG) ?

Treatment

Treatment of secondary seizures is aimed towards treatment of the underlying cause. The treatment of intra-cranial disease may be surgical (e.g. meningiomas), medical (e.g. *Toxoplasma gondii* infection, lymphoma), or symptomatic with drugs designed to control the seizure, without treating the underlying disease. The same drugs are generally used to manage symptomatic seizures as are used for idiopathic and cryptogenic epilepsy. Once treatment for seizures is started, it should not be withdrawn rapidly, as severe withdrawal seizures may develop.

Phenobarbitone

Phenobarbitone is the most commonly used drug to control seizures. It binds to the GABA receptor, thereby mimicking the action of GABA as an inhibitory neurotransmitter. The dose required for cats is generally less than for dogs, but the pharmacokinetics (i.e the rate of absorption and metabolism) are much more variable than in dogs, which makes monitoring

of drug levels potentially of more importance in cats than in dogs. Monitoring may entail measurement of peak plasma concentrations if toxicity is of concern, and trough plasma concentrations if lack of efficacy is of concern. Peak plasma concentrations are generally measured 2 hours post pill, and trough levels are measured just prior to administration of medication. Phenobarbitone also comes in an elixir form, which may enable more accurate dosing in cats, and may facilitate administration.

Side effects associated with phenobarbitone include sedation, increased appetite and thirst/urination and pruritus (itch). Liver enzymes may be raised on blood tests, but this reflects liver metabolism of the drug, rather than liver damage. Interactions with other drugs that are metabolized by the liver are common, as are interactions with drugs that are protein bound.

Benzodiazepines

Benzodiazepines such as diazepam and clonazepam work in a similar fashion to phenobarbitone, by binding to the GABA receptor. Because diazepam can be administered intra-venously, it is often used as first-line management to control seizures in the clinical setting (e.g. status epilepticus). Again, increases in appetite and thirst/urination and sedation may be seen as side effects. Occasional cats have suffered from fatal, idiosyncratic, fulminant liver failure, but unfortunately, because these reactions are idiosyncratic, it is not possible to tell in advance which animals may be affected by this type of reaction. Physical dependence to the benzodiazepines may develop.

Tolerance to phenobarbitone and the benzodiazepines may occur. These drugs stimulate the enzymes that are responsible for their metabolism (induction). Enzyme induction means that the drug is broken down more rapidly, therefore with continued use increased dosages may be required.

Potassium bromide

This drug is being increasingly used for control of canine seizures, either on its own, or in combination with phenobarbitone. It may enabled reduced dosages of phenobarbitone to be given, thereby resulting in fewer side effects such as sedation, and is the preferred anti-convulsant in cases of liver disease. Potassium bromide has also been used for control of seizures in cats. Up to one third of cats developed asthma on this drug, and in some cases this was so severe as to be fatal. The use of this drug in cats, particularly if they have a history of asthma, therefore, *cannot be recommended*.

TABLE 1 - DIFFERENTIAL DIAGNOSTIC LIST FOR SEIZURES

category	group	specific disorders
DEGENERATIVE	LYSOSOMAL STORAGE DISEASES	Gangliosidosis, mannosidosis, NiemannPick disease
ANOMALOUS	BIRTH DEFECTS	Hydrocephalus, cysts
METABOLIC	LIVER DISEASE	Portosystemic shunts
	KIDNEY DISEASE	Chronic renal failure
	HYPOGLYCAEMIA	Insulinoma
	HYPERGLYCAEMIA	Diabetes mellitus
	HYPERNATRAEMIA	Salt poisoning
	HYPOCALCAEMIA	Hypoparathyroidism; eclampsia
	HYPERLIPIDAEMIA	Rare in cats; ?LPL deficiency
NEOPLASIA	PRIMARY BRAIN TUMOURS	Meningioma, glioma, pituitary
	SECONDARY BRAIN TUMOURS	Lymphoma, mammary, nasal, lung
NUTRITIONAL	THIAMINE DEFICIENCY	White fish diet
INFECTIOUS	VIRAL	FIP, FeLV, FIV, panleucopenia, Borna disease, Rabies
	BACTERIAL	<i>Bartonella henselae</i>
	PROTOZOAL	<i>Toxoplasma gondii</i>
	FUNGAL	<i>Cryptococcus neoformans</i>
INFLAMMATORY	ENCEPHALITIS	
	MENINGITIS	
IDIOPATHIC	EPILEPSY	
TRAUMA		RTA, kicks, dogs
TOXIC	HEAVY METALS	Lead
	INSECTICIDES	Organophosphates, carbamates
VASCULAR	INFARCTION	Feline ischaemic encephalopathy
	THROMBO-EMBOLISM	Cardiac disease, septic embolus
	HAEMORRHAGE	Thrombocytopenia. Coagulopathy, trauma, hypertension
	HYPERVERSICOSITY	Polycythaemia, hyperglobulinaemia

What clues can the skin can give us about the presence of systemic diseases?

Andrea Harvey

*RCVS Specialist in Feline Medicine & European Veterinary Specialist in Internal Medicine
FAB Clinical Associate, University of Bristol Veterinary School*

The presence of skin abnormalities such as hairloss, redness, scaling and ulcerations does not always mean that disease is limited to the skin. In some cases, certain features of skin disease can give important clues about the presence of a more serious underlying disease.

This lecture will focus in particular on three cats with unusual and serious diseases, where skin disease was the presenting complaint. Recognising the clues given by the skin makes all the difference in reaching a correct diagnosis, and where possible, treating the underlying disease.

Case 1: Paraneoplastic alopecia

A 11 year old FN DSH presented with a 3 week history of lethargy and progressively worsening dermatological signs consisting predominantly of alopecia (hair loss) and erythema (reddening) of the ventrum, limbs and nail beds.

On presentation she was reasonably bright and alert and in good body condition. Physical examination revealed crusting around the nose and pinnae (ears), extensive erythema and alopecia of the inner part of the limbs and ventrum, easily epilated hair in non-alopecic areas, hyperpigmentation and alopecia around the perineum, generalised scale and erythema and alopecia around the nailbeds with erythema and thinning of the foot pads.

The main possible causes for these skin signs include:

- Paraneoplastic alopecia (= hair loss associated with cancer of internal organs)
- Immune mediated disease – e.g. pemphigus foliaceus
- Hepatocutaneous syndrome
- Infectious disease – dermatophytosis (fungal infection), demodicosis (demodex mites), ectoparasites
- Endocrinopathies – hyperadrenocorticism (Cushings disease), telogen defluxion
- Allergic disease – flea allergy, cutaneous food/drug reactions, atopy

Skin scrapes, brushings and hair plucks were taken to look for ectoparasites and demodex. None were identified. Examination with a Woods' lamp which looks for certain skin fungi was negative.

Routine haematology was unremarkable except for a mild mature neutrophilia (elevated white blood cells). Biochemistry revealed mild elevations in ALT, ALP (liver enzymes) and globulins (proteins). Dynamic bile acids (a test of liver function) were significantly elevated indicating liver dysfunction.

Thoracic radiographs were unremarkable. Abdominal radiographs did not reveal any abnormalities except for poor detail immediately caudal to the liver. Abdominal ultrasound revealed a large mass in the liver with smaller nodules and disruption of normal hepatic architecture throughout the liver.

Given the likelihood that this was a form of cancer and was associated with the skin disease, the owners elected for euthanasia at this stage.

Post mortem examination revealed a white firm nodule 0.6 cm in diameter in the pancreas with several smaller irregular nodules scattered throughout the pancreas. The liver also contained many scattered white/grey irregular firm nodules throughout. The lungs also contained several small white firm nodules.

Histopathology (looking at sections of tissue under the microscope) revealed the nodules to be an adenocarcinoma, which is a type of malignant cancer, and it looked like this had originated in the pancreas and spread to the liver and lungs.

Skin histopathology showed changes paraneoplastic alopecia (mild mononuclear inflammation, epidermal hyperplasia and telogenisation of hair follicles).

Feline paraneoplastic alopecia (FPA) has been reported in 12 cats with pancreatic carcinomas (malignant tumour of the pancreas) and 2 cats with biliary carcinomas (malignant tumour of the bile ducts). The main presenting sign in these cases has always been alopecia progressing from the ventrum (under the abdomen) to the head and predominantly the inner aspects of the limbs. In non-alopecic areas the hair is easily epilated. The appearance of the skin appears to be very characteristic, with a shiny, inelastic and thin appearance, without the fragility seen with hyperadrenocorticism (Cushing's disease). Foot pad involvement is also commonly seen with variations from erythematous, transparent glossy pads, as seen in this case, to dry and crusty foot pads, where hepatocutaneous syndrome would be an important differential. Histopathology of the skin is also characteristic revealing follicular telogenization and atrophy. Cats with the condition tend to have non-specific signs of systemic illness such as lethargy and anorexia.

The prognosis for the condition is unfortunately grave. In the majority of cases, as in this one, the disease has spread to other organs by the time it is diagnosed. Resolution of dermatological signs has been reported in one case following surgical resection of a pancreatic neoplasm (Tasker et al 1999) however recrudescence occurred 18 weeks later.

These striking skin abnormalities should alert clinicians to the possibility of FPA, prompting a search for cancer of internal organs. If caught early enough, removal of the tumour may alleviate clinical signs for a period of time.

Case 2: Thymoma (benign tumour of the thymus gland)

A 9year old MN Burmilla presented with a long history of skin problems, which had been diagnosed as a disease called pemphigus foliaceus, based on biopsies taken from the skin. This type of skin disease is caused by the formation of antibodies against molecules in the skin that are responsible for keeping the layers of the skin stuck together. Antibodies formed by the animal against these molecules results in disruption in skin layers causing vesicles and pustules to form, which often progress to ulceration of the skin and secondary infections. This disease can be an autoimmune disease, where the body itself produces the antibodies, or can occur secondary to other diseases, such as some types of tumours, where the tumour cells produce the antibodies.

Following the results of the skin biopsies, the veterinary surgeon took x-rays of the cats chest which revealed a mediastinal (area in front of the heart) mass. The cat was then referred to University of Bristol for further investigation.

On presentation he was quiet but alert. He had ulcerated areas of skin particularly around the face and pinnae, and also more generalised scales. The remainder of the physical examination was unremarkable.

Routine haematology and biochemistry were largely unremarkable. FeLV and FIV tests were negative.

The mass was examined in more detail with ultrasound, and an ultrasound guided biopsy was taken. Histopathology (examination under a microscope) confirmed this to be a thymoma, which is a benign tumour of the thymus gland.

Surgery was performed and the thymoma was successfully removed in its entirety.

The facial ulceration dramatically improved following surgery but due to the severe secondary bacterial infections on the skin underneath the abdomen, Oki required regular bathing and antibiotic treatment to treat these. Only time will tell if his skin problems completely resolve after having removed the thymoma or whether he will require any further treatment.

These type of tumours (thymomas) have been associated with a number of skin diseases in cats, including paraneoplastic alopecia as described in case 1. The most common type of skin disease associated with thymomas however is one called exfoliative dermatitis. This is characterised by dry scaly scurfy skin initially developing on the head, neck and ear pinnae and eventually becoming more generalized all over the body.

The main possible causes for these skin signs include:

- Chyletiella (a type of mites often found on rabbits)
- Allergies
- Dermatophytosis (fungal infection)
- Drug reactions
- Autoimmune skin conditions
- Epitheliotropic lymphoma (a type of skin tumour)

Case 3: Hyperadrenocorticism (Cushing's Syndrome)

See Angie Hibbert's talk 'Sophie's skin' for case details

Hyperadrenocorticism, is a disease that develops when there is a chronic excess of the hormone cortisol, circulating in the bloodstream. It can result in a variety of skin abnormalities, which may be the cat's initial presenting complaint. In cats with hyperadrenocorticism, they sometimes have a particularly striking skin abnormality whereby because the skin is so fragile, it very easily tears, just like a piece of paper. This can be very problematic as even just picking the cat up can result in large skin tears. Furthermore, the disease reduces the ability of the skin to heal, and so these skin tears once they occur are difficult to manage because they do not heal easily.

The disease can occur secondary to the long-term administration of corticosteroid drugs, or it may be due to naturally occurring disease whereby an excess of cortisol is produced by the adrenal glands, which are 2 small glands situated near the kidneys. Excess cortisol production by the adrenal glands can be caused by an adrenal tumour, or by a pituitary gland (a small gland at the base of the brain) tumour. Pituitary gland tumours produce another hormone, called adrenocorticotrophic hormone (ACTH), which stimulates the adrenal glands to produce excessive amounts of cortisol.

When Cushing's disease is caused by an adrenal tumour it is termed adrenal dependant Cushing's (or adrenal dependant hyperadrenocorticism), and similarly when it is caused by a pituitary gland tumour, it is termed pituitary dependant Cushing's (or pituitary dependant hyperadrenocorticism). In about 50% of cases caused by adrenal gland tumours, the tumour

is malignant (carcinoma), and in 50% of cases it is benign (adenoma). The majority of pituitary tumours causing the disease are benign very tiny tumours (usually 3-4mm in diameter), but occasionally larger tumours and malignant tumours can occur.

The disease is uncommon, with only 70 cats with the syndrome having been reported in the veterinary literature in the last 15 years. All the causes of Cushing's syndrome in cats are uncommon, much less common than the disease is in dogs. Owners should always be aware however, of the signs to look out for if their cat is receiving chronic corticosteroid treatment for whatever reason. With the naturally occurring form of the disease, pituitary gland tumours are much more common than the adrenal gland tumours.

The disease occurs in middle-aged and older cats. A variety of breeds have been affected including Siamese, Persian, Abyssinian and Domestic Long Hairs, but the majority of cats that have been affected are Domestic Short Haired cats.

Many different signs can occur, including excessive drinking and urination (polyuria/polydipsia), increased appetite, enlargement of the abdomen, lethargy, muscle wasting, poor coat condition/hair loss, curling of the ear tips and the development of very thin and fragile skin. The skin can be so fragile that it very easily bruises, and also can very easily tear.

The majority of cats with Cushing's disease also have Diabetes Mellitus because cortisol interferes with the affects of insulin. Because of this interference, the diabetes is difficult to control even when insulin is administered by injection. One of the most common reasons for suspecting Cushing's Syndrome in a cat therefore, is the development of diabetes that is very difficult to control despite administering high doses of insulin. In this situation the most commonly seen signs are those associated with the diabetes (polyuria/polydipsia, increased appetite, weight loss).

Diagnosis of Cushing's Syndrome is not always straightforward and usually requires multiple blood tests, urine tests and diagnostic imaging.

The first blood tests that would usually be performed are routine haematology and biochemistry. Doing these basic tests first are important to rule out other more common diseases, for example kidney disease and hyperthyroidism and assessing for diabetes mellitus. Analysis of the urine may also be helpful in assessing kidney function, diabetes mellitus and also to look for bacterial infection in the bladder, as this is a common complication of both Cushing's Disease and diabetes mellitus.

Diagnosis of Cushing's Syndrome caused by long-term corticosteroid administration is usually based on the knowledge of this treatment being given and the development of typical clinical signs and blood abnormalities. However, the naturally occurring form of the disease is more difficult to diagnose and other urine tests and more specialised blood tests (ACTH stimulation, dexamethasone suppression tests) will be required. These blood tests require multiple blood samples to be taken throughout the day, so your cat would need to be hospitalised for a day or two in order for these tests to be performed.

Once Cushing's Disease has been diagnosed, further blood tests and also imaging (X-rays and ultrasound +/- CT/MRI scan) may be required to determine whether the disease is being caused by an adrenal tumour or pituitary tumour, before the best treatment option can be decided.

If the disease has been caused by long-term administration of corticosteroids, then these drugs need to be stopped. It is very important however that they are not stopped immediately as this can have severe consequences, as the cat will have become dependant

on corticosteroid administration. It is therefore important that the dose of the corticosteroids is gradually reduced over a period of time until they are eventually stopped. The time required for weaning off the treatment will depend to some extent on the dose and length of time the cat has been receiving the corticosteroids.

When the disease is caused by an adrenal tumour, the best treatment is for that adrenal gland to be removed (adrenalectomy). Unfortunately this surgery is fairly high risk because the high levels of circulating cortisol predispose the cats to infections and thromboembolism, and reduce wound healing. In addition, the adrenal glands are situated very close to a large major blood vessel (caudal vena cava) so severe haemorrhage is another potential complication.

Treatment of pituitary tumours is unfortunately even more problematic, as there is no one satisfactory treatment available. In humans the treatment of choice is surgical removal of the pituitary tumour (hypophysectomy). This is an extremely technically difficult surgery and although this surgery is being attempted in some parts of the world, it has only been performed in a very small number of cats to date.

Another potentially useful treatment for pituitary tumours is radiation therapy, however this treatment is not widely available, and again not many cats have been treated in this way. It therefore remains to be seen how successful radiation therapy is, and what side effects may be encountered.

A wide variety of medical treatments have also been tried for both adrenal and pituitary dependent Cushing's disease, such as ketoconazole, metyrapone and aminoglutethimide. Unfortunately there has been very variable success with these drugs, with some cats not responding to treatment at all. Mitotane used to be the treatment of choice for dogs with this disease, but this drug appears to have little effect on the disease in cats. Recently, a newer drug, Trilostane has been licensed for the treatment of Cushing's disease in dogs, and now is the treatment of choice in dogs. Trilostane has not yet however been widely used in cats, but so far there have been a few promising reports so this may prove to be a useful treatment in the future.

Unfortunately Cushing's Syndrome is a serious disease and carries with it a guarded to poor prognosis. Treatment options are very limited, treatment can be expensive, stressful for the cat and owner, and unfortunately there is no guarantee of treatment being a success. Even with 'successful' treatment less than 50% of cats afflicted with the disease will survive beyond a year. Hopefully, in the future newer treatment modalities will become available improving the outlook of cats with Cushing's disease.

Sophie's Skin – A case of hyperadrenocorticism

Angie Hibbert

Feline Advisory Bureau Resident, University of Bristol

Sophie, a 7 year old female neutered grey tortie domestic shorthair was referred to the Feline Centre at the University of Bristol with a long history of excessive thirst and frequent urination. She had also developed multiple skin wounds over her chest walls, which had failed to heal despite treatment.

On examination Sophie was found to be extremely dull and depressed. She had several wounds over both sides of her chest, the largest being 6x4cm. Of additional interest was the finding of thin skin which was bald over Sophie's chest and neck. These were areas where Sophie's coat had been previously shaved to allow her wounds to be cleaned and the hair had not regrown after 5months.

Sophie's history and physical examination made us suspicious of a condition called **hyperadrenocorticism** (or Cushing's syndrome). A series of tests were performed to investigate this including routine blood tests, urine analysis, endocrine function tests and abdominal ultrasound.

These tests confirmed that Sophie did have hyperadrenocorticism. The condition is diagnosed frequently in dogs however it is rare in cats. Feline hyperadrenocorticism is a serious disease with a guarded to grave prognosis, without treatment most cats die within a few weeks to months.

Patients with hyperadrenocorticism have excessive amounts of cortisol (stress hormone) in the bloodstream. The underlying cause is either a tumour in the adrenal glands (where cortisol is produced) or a tumour in the pituitary gland in the brain. Sophie's test results suggested she had the pituitary form. She was also found to have high blood and urine glucose levels suggestive of diabetes mellitus; this was thought to have been a recent development as she had been tested for diabetes previously. High levels of circulating cortisol were responsible for the development of Sophie's thin fragile skin and secondary diabetes mellitus.

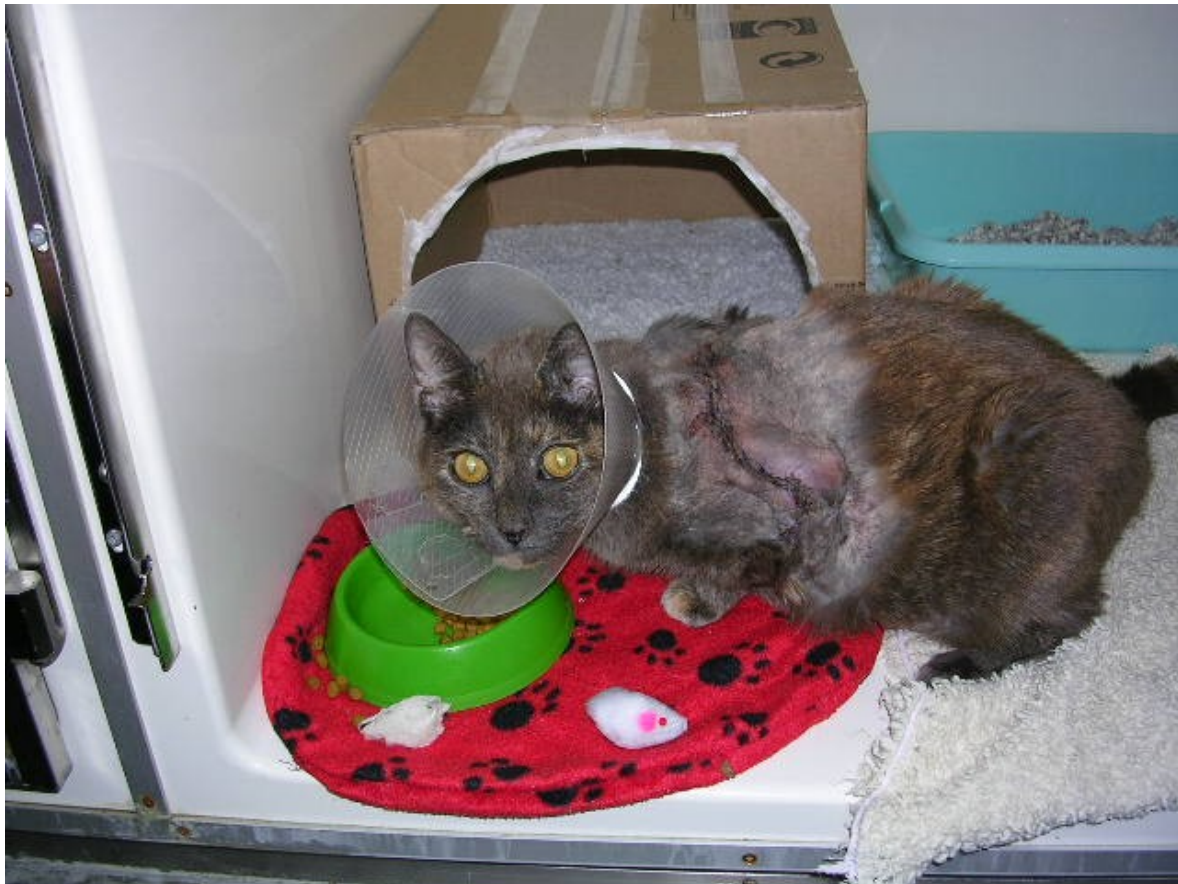Once the diagnosis had been made Sophie was prescribed trilostane, a drug that blocks the formation of cortisol. This drug is licensed for the treatment of Cushing's disease in dogs, but has only been available for a few years. A recent veterinary publication had reported encouraging results in 5 cushingoid cats treated with trilostane. The drug however is not licensed for use in cats. Despite this and the limited reports we decided to treat Sophie with trilostane; in the past a handful of other drugs had been used to treat hyperadrenocorticism in cats, unfortunately these had all been associated with unacceptable side-effects or were ineffective. Sophie was also treated with antibiotics and pain-killers and was fed a diet designed specifically for diabetic patients.

Sophie responded well to treatment with a significant improvement in her demeanour and reduction in her thirst levels (and glucose levels). Unfortunately however her skin remained extremely fragile and as she stepped into her cage one afternoon the largest wound tore all the way down her side. The following day Sophie was taken to surgery and the wound was pain-stakingly closed. The surgery was technically difficult as her skin was paper-thin. Miraculously Sophie's wound healed and she was able to return home.

Sophie enjoyed the summer months back at home with her owner and brother 'Badger', we heard tales of her getting up to her old tricks such as chasing dragonflies in the garden. As a precaution she (happily!) wore a protective coat when unsupervised, this had been

specifically designed and made for her by her owner. We closely monitored her and were pleased that blood tests indicated a good response to therapy. Unfortunately five months later a small scratch on her neck became infected and the skin tore once more. This time however Sophie became extremely sick; she was running a fever and was anorexic (most unusual for her!). Sophie returned to Langford for surgery. She made a full recovery and tolerated all of her treatments fantastically.

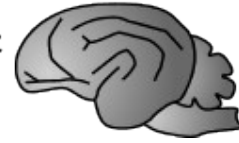Sadly Sophie developed severe pancreatitis (inflammation of the pancreas) a few months after her second surgery and despite intensive treatment did not recover. Pancreatitis was likely a consequence of both the hyperadrenocorticism and secondary diabetes. Despite this sad outcome Sophie's story is positive, in the past it was often advised that once a cat with Cushing's disease had developed skin tears there was nothing more that could be done to help them. Sophie survived many months after the diagnosis of hyperadrenocorticism had been made and following surgical repair of her skin tears; most importantly she enjoyed a good quality of life whilst being treated. Sophie treatment required the combined efforts of medical and surgical veterinary teams however much credit must also be given to Sophie's owner, who provided meticulous care and lots of TLC to aid her treatment at home.



Sophie recovering at the Feline Centre at the University of Bristol after surgery for a skin tear

Feline orofacial pain syndrome

Face and tongue mutilation in Burmese



C.Rusbridge¹ N. Johnson² S.E. Heath³ D.A. Gunn-Moore⁴

¹ Stone Lion Veterinary Centre, Wimbledon, London, UK, SW19 5AU neuro.vet@btinternet.com

² Scottish Vet Dental Partnership, North Berwick

³ Behavioural Referrals, Chester

⁴ Royal (Dick) School of Veterinary Studies

Introduction

Recently a feline facial pain / mutilation syndrome has been recognised which is especially prevalent in Burmese cats although occasional cases have been seen in the domestic shorthair, Burmilla and Siamese. There may be a slight male predisposition and all ages can be affected.

Clinical signs

The clinical signs are characterised by exaggerated licking and chewing movements, with pawing at the mouth. Typically the discomfort is unilateral or worse on one side and can be episodic or continuous. In the episodic version the distress usually occurs after eating and lasts between 5 minutes and 2 hours. There is a short prodromal period of anxiety preceding the episode. The activity is not suggestive of a seizure; the cat remains alert and can be distracted, although with difficulty. Some cats have continuous discomfort that increases in intensity when excited or stressed. These cats are often anorexic and in considerable distress, requiring paw bandaging and /or an Elizabethan collar to prevent severe mutilation. Some cases appear to be associated with oral disease, which can be divided into 4 groups

1. Mouth ulceration, especially as a consequence of Calici virus infection or primary vaccination
2. Cutting permanent teeth
3. Dental disease, most commonly periodontal disease and dental resorptive lesions.
4. Recent routine dental treatment including extraction.

Treatment of, or natural resolution of the lesions can result in improvement, however many cases have recurrences which proved more difficult to successfully treat. In the kittens the problem resolves when the mouth ulceration/teething does, however these cats may have a recurrence when adult. Other possible influences include stress, either from systemic disease, pregnancy, or environmental factors e.g. a multi-cat household. Spontaneous remission and recurrence is common.

Possible pathogenesis

Orofacial pain disorders are well described in humans. The feline orofacial pain syndrome shows some similarities to trigeminal neuralgia. This disease is characterised by paroxysmal bouts of pain in the distribution of the trigeminal nerve, usually the jaw. The pain is precipitated by trigger factors of which the most common is facial movement e.g. chewing. For trigeminal neuralgia to occur there must be a combination of peripheral disturbance or damage, e.g. dental disease, together with a cerebral brainstem disinhibition of the trigeminal apparatus. This results in a paroxysmal discharge and reverberation of pain impulses when a trigger point is elicited¹. It is for this reason that anti-epileptic drugs are one of the most effective treatments. More unusual human facial pain syndromes include glossodynia (burning mouth syndrome)⁵. This is described as a burning or prickling sensation of the oral mucosa most commonly the anterior tongue⁶. In many of the affected

cats, tongue discomfort seems to be the primary problem and several cases severely mutilated the tongue. There are also facial pain syndromes primarily involving missing teeth (atypical odontalgia or phantom tooth pain), the temporal mandibular joint (temporomandibular pain and dysfunction syndrome) and one where taste is the trigger (gustatory neuralgia)^{5, 6}.

As Burmese cats are predisposed this raises the question of a hereditary susceptibility. The authors' propose that these cats are susceptible to the problem because of a disorder of central processing. They subsequently acquire a peripheral lesion such as dental disease resulting in the orofacial pain disorder. Stress may be a contributory factor. Treatment may be effective initially however there is a high chance of recurrence and treatment may become less effective with time. Many of the affected Burmese cats are closely related. A familial trigeminal neuralgia is recognised (rarely) in humans^{2, 3, 4}.

Work up

Diagnostic work up of affected cats includes ruling out predisposing medical problems, especially dental disease. Specialist opinion and good quality dental radiographs are recommended. Dental resorptive lesions (DRL's or FORL's (syn)) are one of the more common associated diseases and the questionable practice of dental atomisation of retained roots can aggravate the problem. It is also important to explore the history for possible psychological factors, e.g. stress from multi-cat household, and implement appropriate management.

Treatment

Medical treatment is dependant on the underlying disease, if there is one. Some cases with gingivitis have appeared to respond to antibiotics, although spontaneous remission could not be ruled out. NSAIDs were effective analgesia for some mildly affected cases. Opioids were very useful for hospitalised cases; however anti-epileptic drugs (diazepam or phenobarbitone) gave more sustained and consistent relief. Phenobarbitone is the preferred drug because of the greater risk of idiosyncratic hepatic failure with diazepam. Occasionally life-long therapy is required. Some cases, especially those with chronic dental disease, responded to steroid therapy. Finally, selegiline is effective for some and is probably more appropriate for those with a behavioural component or contributing stressful environment. For these cases alterations to the environment and application of behavioural modification is also essential.

Conclusion

A feline orofacial pain syndrome is described. The most common triggers are oral lesions especially dental disease. There are similarities to trigeminal neuralgia and other orofacial pain disorders in humans. The Burmese cat is predisposed and a hereditary susceptibility is suspected. As a general guideline, NSAIDs are the most appropriate first line therapy for mild cases and phenobarbitone for more severe acute or chronic cases.

References

1. Lee KH Facial Pain: trigeminal neuralgia *Annals of the Academy of Medicine, Singapore* 1993 22 193-6
2. Fleetwood IG, Innes AM, Hansen SR, Steinberg GK Familial trigeminal neuralgia. Case report and review of the literature *Journal of Neurosurgery* 2001 95 513-7.
3. Braga FM, Bonatelli AD, Suriano I, Canteras M Familial Trigeminal neuralgia *Surgical Neurology* 1986 26 405-8
4. Kirkpatrick DB Familial trigeminal neuralgia: case report *Neurosurgery* 1989 24 758-61
5. Marbach JJ Medically unexplained chronic orofacial pain. Temporomandibular pain and dysfunction syndrome, orofacial phantom pain, burning mouth syndrome and trigeminal neuralgia *The Medical Clinics of North America* 1999 83 691-710
6. Muzyka BC De Rossi SS A review of burning mouth syndrome *Cutis, Cutaneous Medicine for the Practitioner* 1999 64 29-35
7. Srivani SJ, Keith DA, Kulich R, Mehta N, Maciewicz RJ Posttraumatic gustatory neuralgia: a clinical model of trigeminal neuropathic pain. *Journal of Orofacial Pain* 1998 12 287-92